

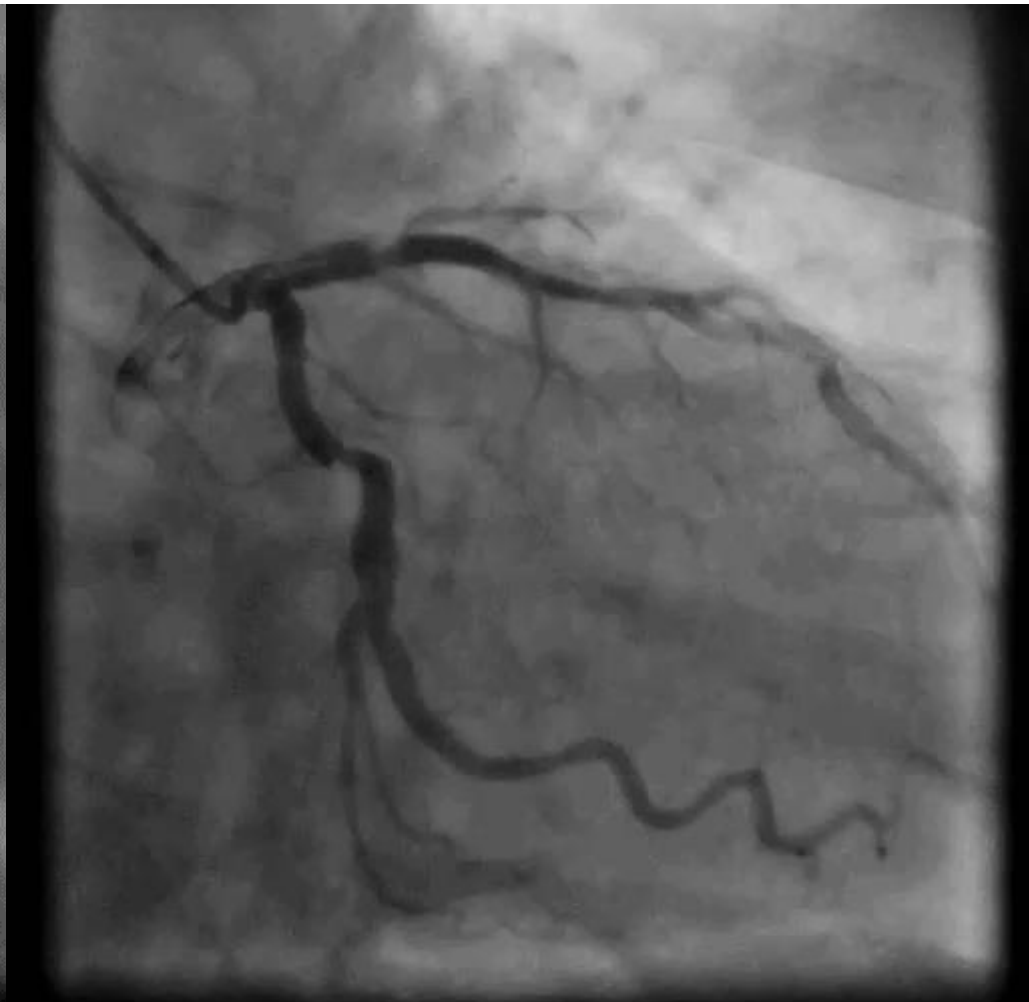
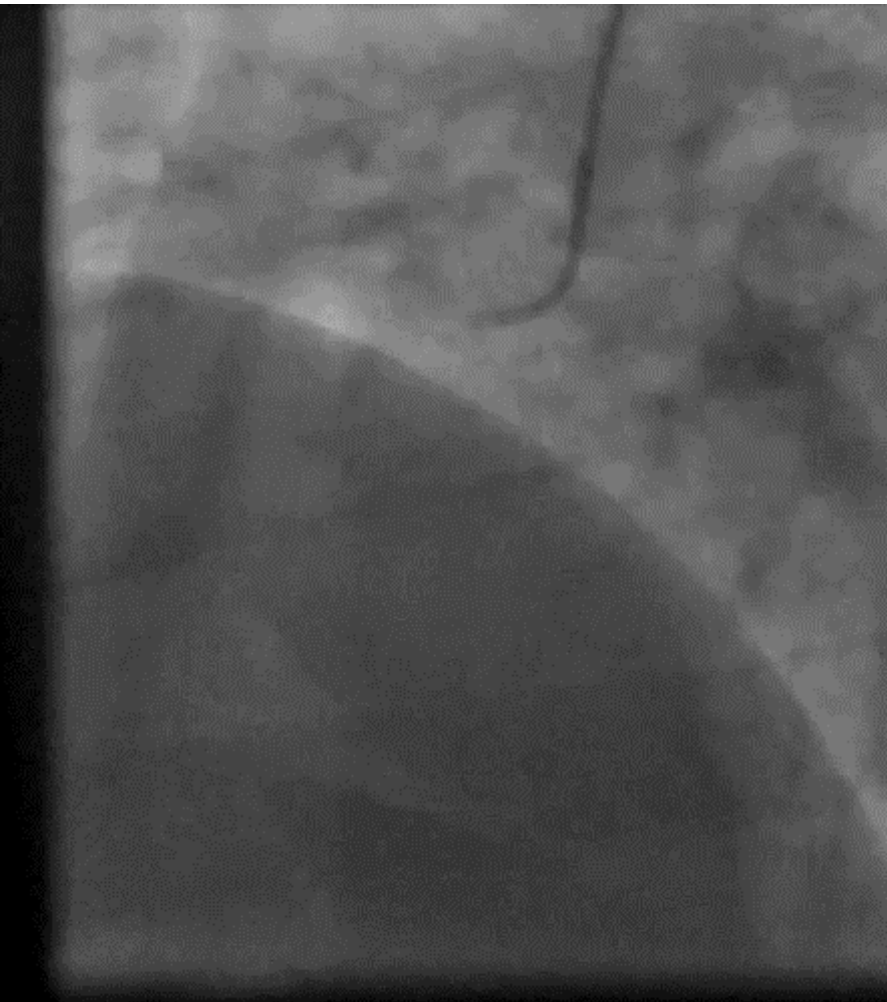
STEMI & Small Aneurism

Dr. Graham Cassel
Milpark Hospital, Johannesburg,
South Africa

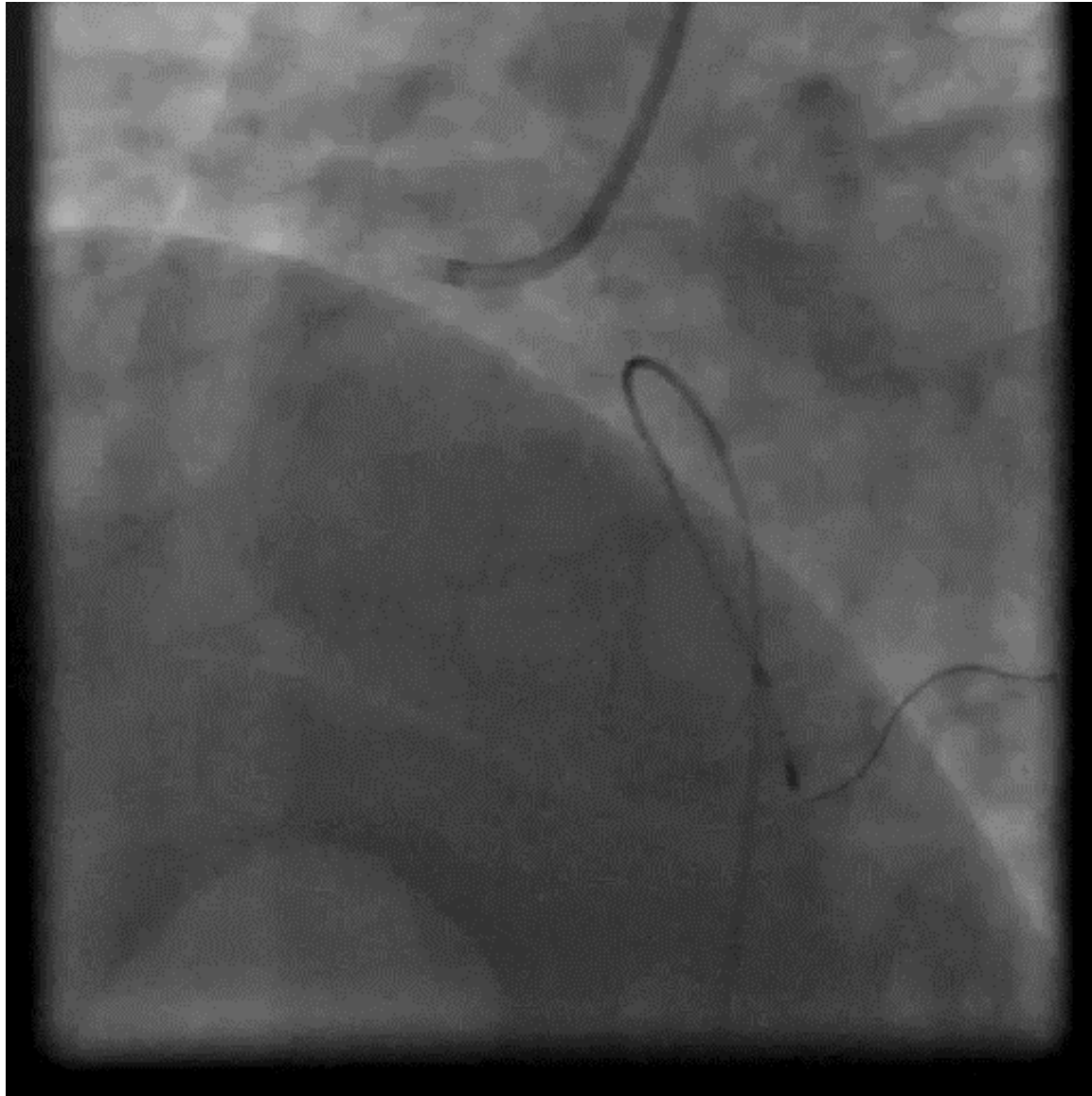
Patient Characteristics

- 52 years old male
- Hypertension, Hypercholesterolemia
- Presented one hour after onset of severe chest pain

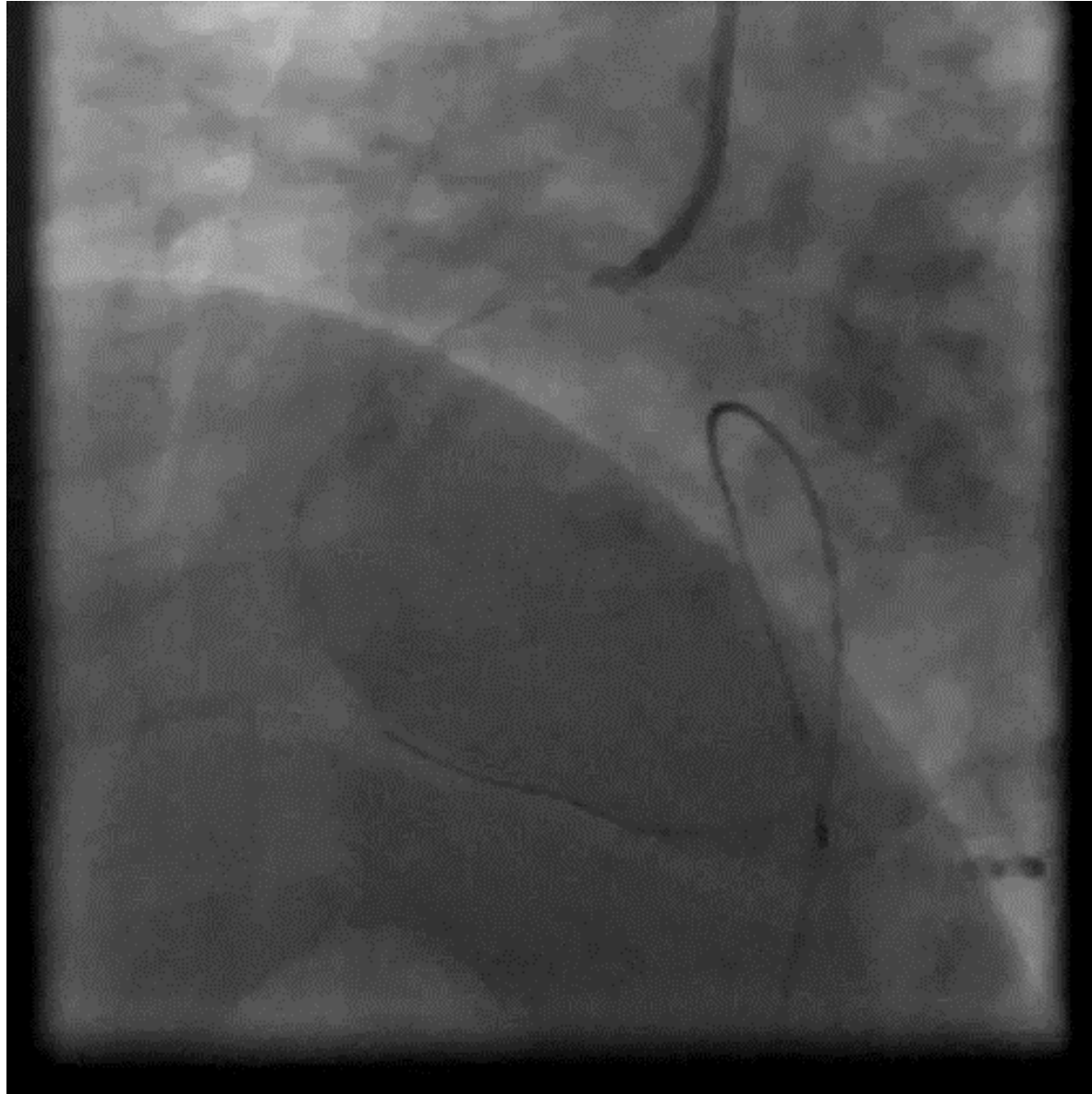
First View – Left & Right



Post Thrombus Aspiration

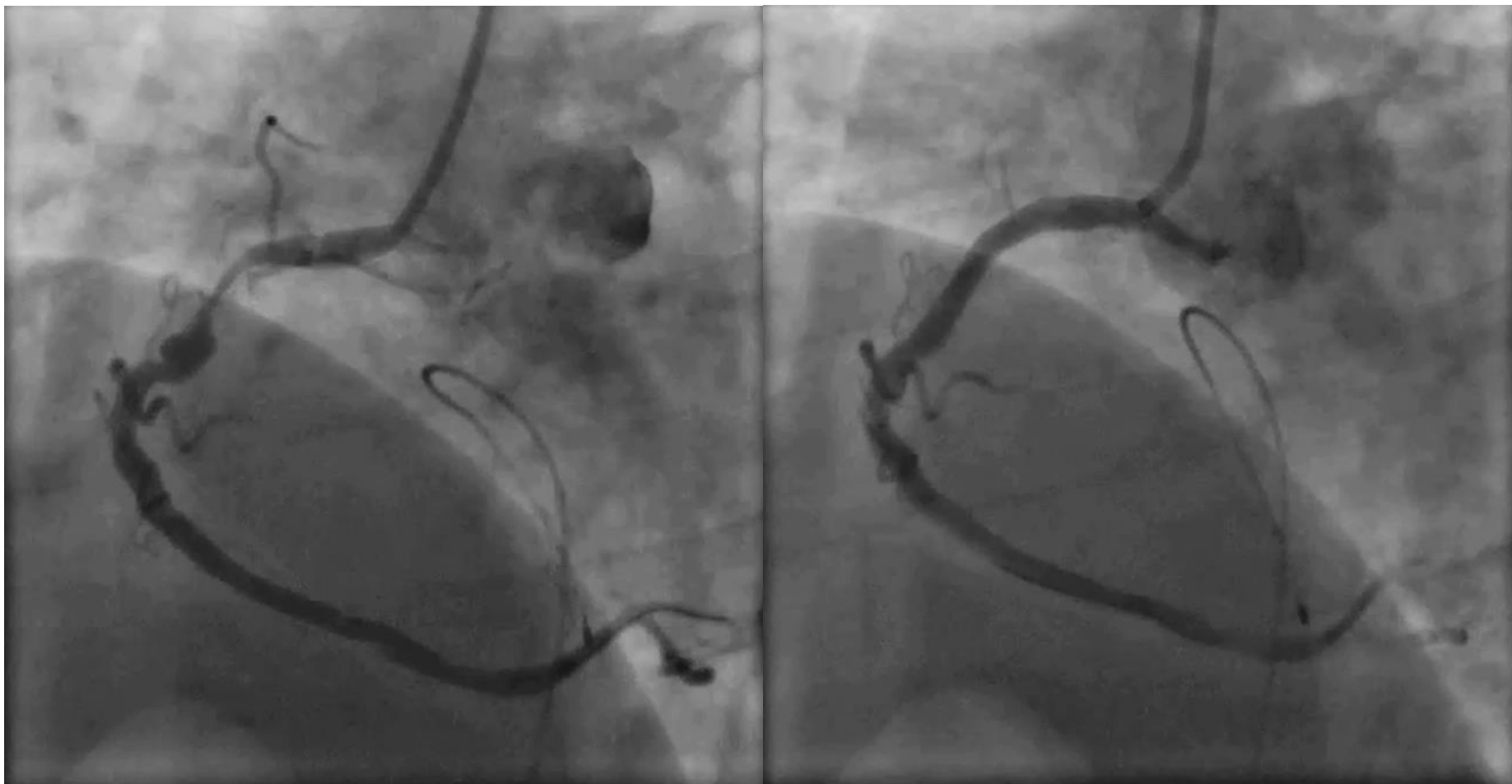


Post MGuard Prime EPS 4X28

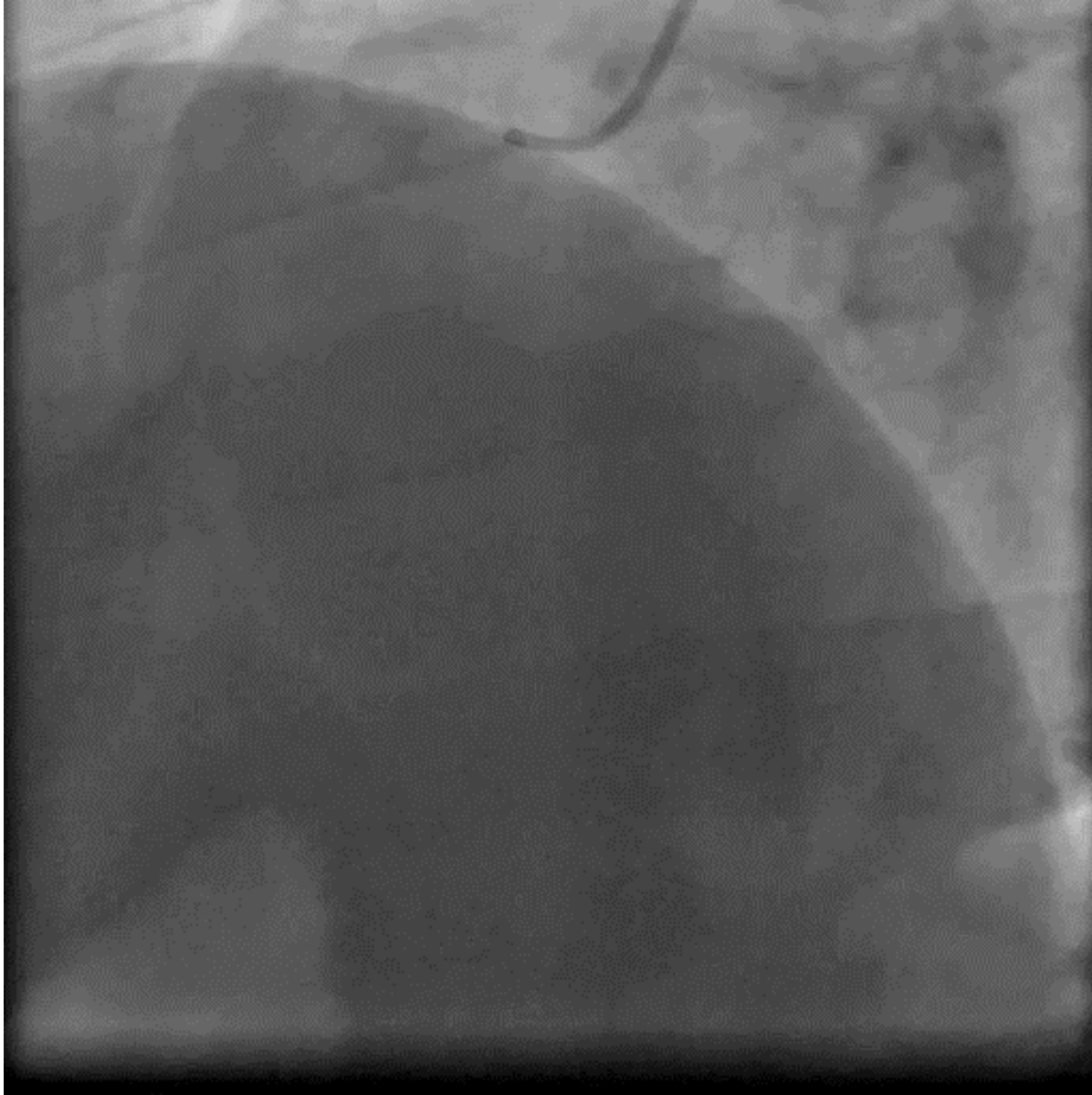


Thrombus & Aneurism

Pre & Post MGuard EPS Implantation



2 Weeks Follow-up (Treating the LAD)



Take Home Message

- MGuard Prime EPS is an excellent solution for the treatment of severe STEMI lesion with aneurysm complicating the stenosis.
- MGuard Prime EPS showed excellent angiographic result.
- Two weeks follow-up: MGuard Prime EPS looked perfect and the two other lesions were treated percutaneously