

# **I Never Expected Result like this.....**

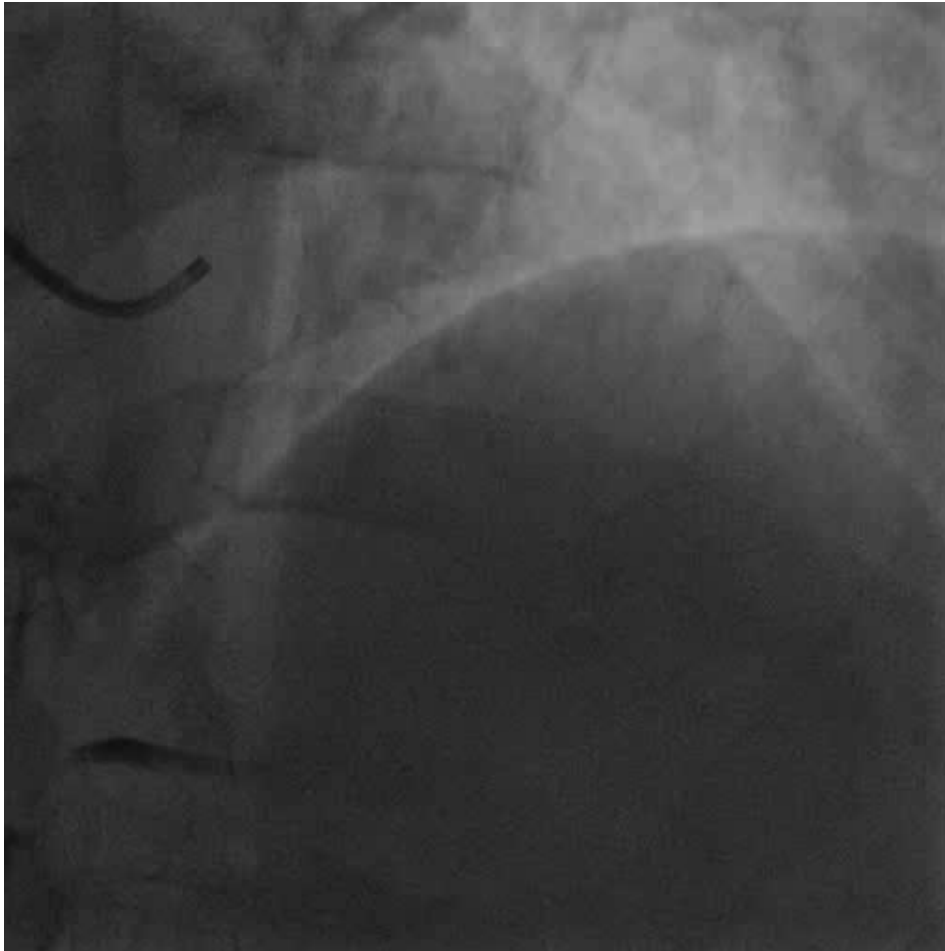
**Carlos Cafri, MD**

*Department of Cardiology, Soroka University Medical  
Center, Faculty of Health Sciences, Ben Gurion  
University of the Negev, Beer Sheva , Israel*

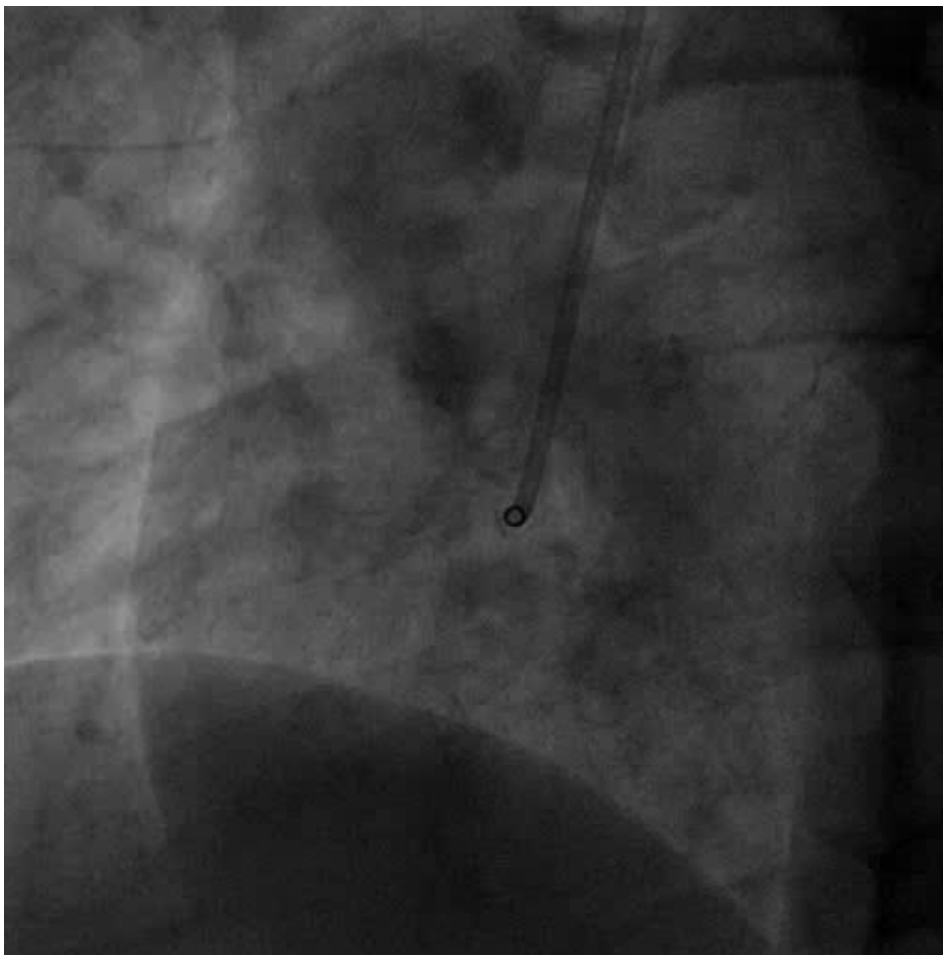
# The Case

- 58 years old men
- DM
- 3 hours of chest pain
- ECG: ST elevation in Inferior wall leads

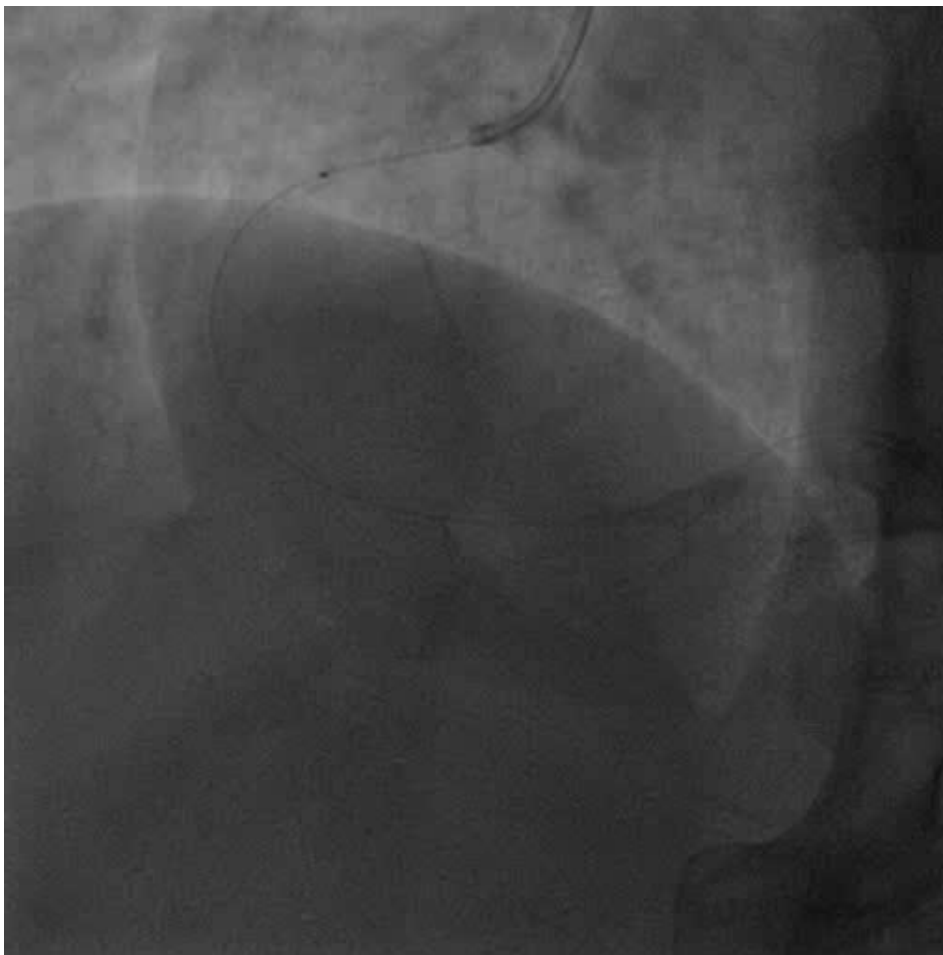# Left System



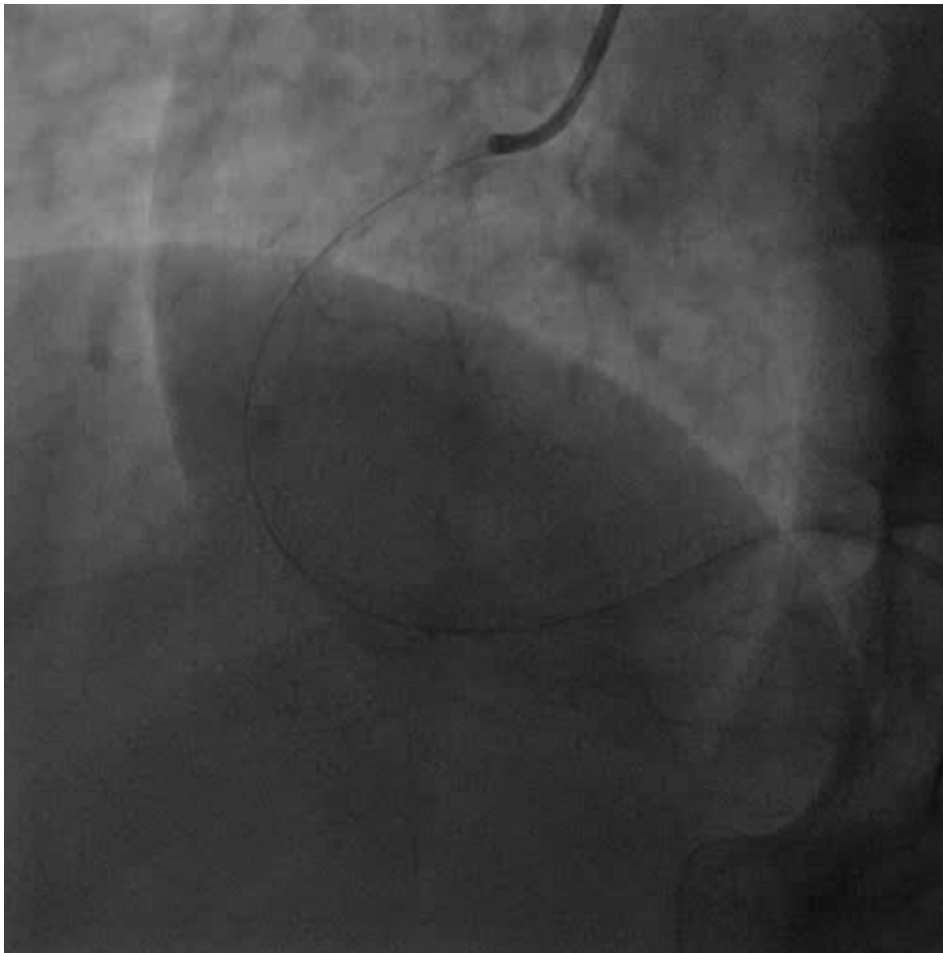
# Urgent Angiography – RCA



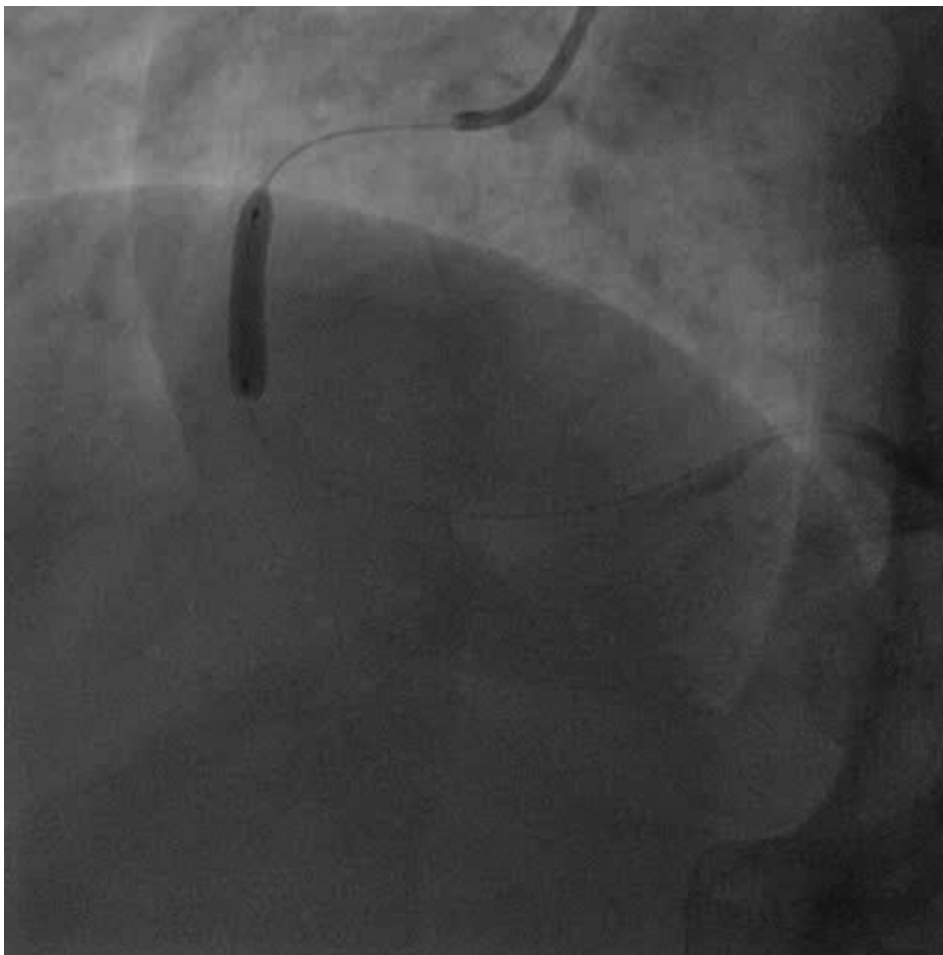
# Manual Thrombus Aspiration



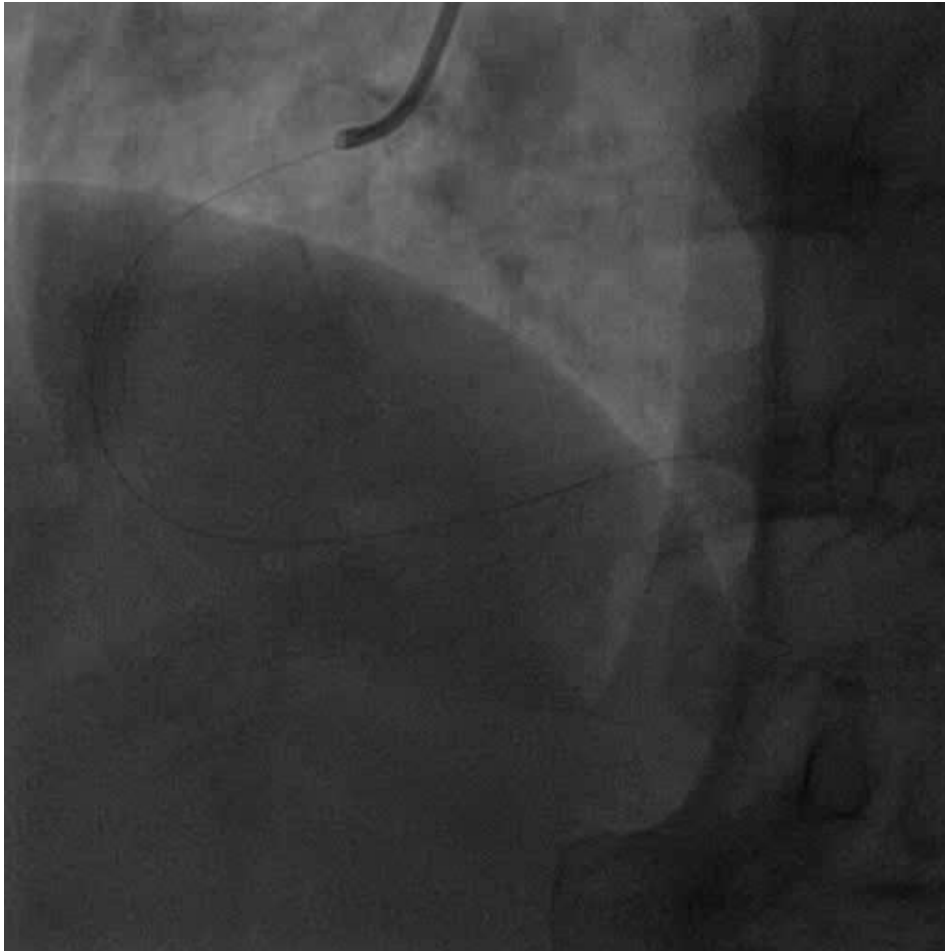# Post Thrombus Aspiration



# MGuard 3.5X18 Implantation



# Final Result





# Take Home Message

- The Embolic Protection Stent (MGuard) allows appropriate management of “impossible” thrombotic situations.
- The efficacy of MGuard EPS in the prevention of coronary emboli is influenced by technical experience.